



Case Report

Multi-level Nerve Injury of the Upper Extremity Management and Review of Brachial Plexus Literature: A Case Report

Monica Pecache*, Rahul Patil, Raya Abughanmi, Tsu Min Tsai

Christine M Kleinert Institute for Hand and Microsurgery, Louisville, United States of America

Email address:

Mpecache@kleinertkutz.com (M. Pecache), doctrahul@yahoo.com.in (R. Patil), md.abughanmi95@yahoo.com (R. Abughanmi), TMT@kkahand.com (T. M. Tsai)

*Corresponding author

To cite this article:

Monica Pecache, Rahul Patil, Raya Abughanmi, Tsu Min Tsai. Multi-level Nerve Injury of the Upper Extremity Management and Review of Brachial Plexus Literature: A Case Report. *International Journal of Clinical and Experimental Medical Sciences*.

Vol. 6, No. 6, 2020, pp. 149-154. doi: 10.11648/j.ijcems.20200606.17

Received: November 20, 2020; Accepted: December 7, 2020; Published: December 11, 2020

Abstract: *Background:* Brachial plexus injuries are complex cases requiring a thorough understanding of nerve physiology and upper extremity anatomy. Standard approaches and management have been developed but certain situations still arise where these are not feasible options. *Objectives:* A case of brachial plexus injury is discussed in this report. The patient was a young male who was referred to our center with weakness of the left upper extremity, C5-C7 distribution. Certain components of his injury, such as extensive soft tissue scarring and identification of a long neuroma at the injury site, obliged the surgeons to use unconventional nerve transfers during his surgery. In this paper, we discuss these alternative options in order to support their potential use in complex brachial plexus cases. Other concepts such as single fascicular harvest for nerve transfers and nerve graft augmented nerve transfers are discussed as they were successfully used in this report. *Methodology and Results:* The patient underwent a total of five surgeries which were a combination of nerve and tendon transfers. Some nerve transfers were augmented with long autologous nerve grafts reaching up to fifteen centimeters in length. Throughout the patients sequence of surgeries, certain nerves, such as the ulnar nerve branch to the flexor carpi ulnaris, successfully served as a donor nerve in more than one occasion. Muscle groups where single nerve fascicles were previously used as a donor nerves also yielded adequate muscle strength and were successfully subsequently used in tendon transfers. Ultimately, the patient was able to achieve good muscle strength, range of motion and outcome scores on his left upper extremity after two years from his final surgery. *Conclusion:* This report offers multiple alternative options in managing complex brachial plexus cases as well as challenges some concepts in nerve grafting. Alternative donor nerves are offered for transfers, some of which are not previously used in literature. Aside from this, the use of long autologous nerve grafts, single fascicular nerve transfers and repeated use of certain nerves as donor were performed successfully. We hope these procedures and techniques can be added to each hand specialist arsenal for managing complex brachial plexus injuries, specifically when the standard techniques are not feasible.

Keywords: Peripheral Nerve Injury, Brachial Plexus Injury, Multi-level Nerve Injury, Outcome Following Brachial Plexus Injury, Nerve Transfers, Tendon Transfers

1. Introduction

Brachial plexus injuries (BPI) are one of the most devastating injuries to the upper extremity and pose long term impact on a patient's physical, social, and psychological wellbeing. [1, 2] Extensive research has been done for BPI's in order to search for effective means of offering these patients a

predictable and efficient way to regain upper extremity function. The development of nerve transfers has significantly affected BPI management due to the excellent outcomes it has produced. [2, 3] Recommended transfers have since been established for each type of BPI. In spite of this however, surgeons must stay prudent and keep in mind that each BPI is different. Instances still arise when conventional nerve transfers are not viable options for a patients case. This article

aims to provide readers with alternative options and combinations for performing nerve transfers by presenting a case of brachial plexus and peripheral nerve injury where conventional transfers were not performed. Due to the extensive scarring and other intra-operative findings, the surgeons in this case explored alternate options which ultimately proved effective in restoring upper extremity function.

The paper also explores the boundaries of nerve graft augmented transfers and multiple subsequent single fascicular nerve transfers as this report demonstrates success in extensively performing both concepts.

2. Case Report

A thirty-one-year old male was referred to our center two months after he was involved in a motor vehicular accident. He was noted to have persistent weakness of his left upper extremity following the mentioned trauma. His initial injuries included a left shoulder and elbow dislocation, a radial shaft fracture and multiple lacerations and abrasions over the left

upper extremity. He was initially managed at another center where, closed reduction of the elbow and shoulder dislocations were performed and open reduction, internal fixation of the radial shaft fracture was done. Because of the noted left upper extremity weakness, magnetic resonance imaging of the neck was done but failed to reveal any avulsion injury to the plexus. This lead to subsequent referral to our institute for further management of suspected distal nerve injuries.

The only functioning muscle group on the patients’ initial assessment were the wrist and finger flexors and the ulnar nerve innervated intrinsic muscles (See table 1). A nerve conduction study was done and supported clinical examination findings and revealed injury to the upper and middle trunks of the left brachial plexus with lack of evidence of re-innervation. The patient had radiographs of the glenohumeral joint, which revealed early subluxation of the shoulder, suggesting weakness of the rotator cuff muscles. All findings were explained to the patient and after discussing our plans and patient options, the patient consented and was prepared for brachial plexus exploration and possible nerve transfers/reconstructions.

Table 1. Pre-operative evaluation of patient followed by succeeding examinations after each surgical intervention.

Muscle group Function	Initial eval.	Post- op # 1	Post- op #2	Post- op #3	Post- op #4	2 years post-op
Shoulder abd.	0/5	flicker	2/5	3/5	3/5	>90° 3/5
Shoulder add.	2/5	2/5	3/5	3/5	3/5	3/5
Elbow Flexion	0/5	2/5	2/5	3/5	3/5	4/5
Elbow extension	0/5	2/5	2/5	2/5	3/5	3/5
Wrist flexion	0/5	4/5	4/5	4/5	5/5	5/5
Wrist extension	0/5	0/5	2/5	2/5	3/5	3/5
Finger flexion	4/5	3/5	3/5	4/5	5/5	5/5
Finger extension	0/5	0/5	0/5	2/5	3/5	3/5
Intrinsic muscles	4/5	4/5	4/5	4/5	4/5	4/5

The patients first surgery was performed four months from his initial injury. The surgical team performed an exploration of the supra and infraclavicular plexus which revealed an

extensive neuroma-in-continuity from the paraspinal area extending approximately two centimeters below the clavicle along the C5-C7 roots. (Figure 1).

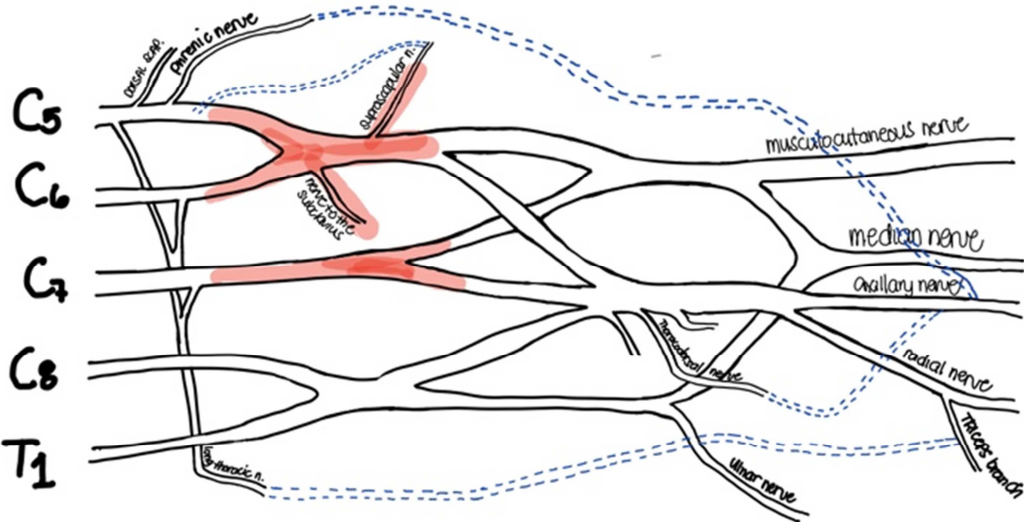


Figure 1. Illustration of identified zone of injury on initial surgery. Red – zone of neuroma, dotted lines – nerve transfer performed.

Further dissection was done and a few healthy fascicles of the C5 root were identified, but no healthy fascicles from the C6 and C7 root were discovered. The Extensive scarring over

the area made dissection and identification of structures additionally challenging. The following intra-operative decisions were made in light of their findings: 1) the C6-C7

neuroma was left undisturbed. The neuroma in the area was long and no healthy nerve tissue was could be isolated. Since excising such a long span of nerve tissue would consume time and did not offer any clinical improvement, it was decided that it would be left alone. Any possible reinnervation from these roots, at least in more proximal areas, could occur if healthy nerve tissue was simply not identified during the assessment. 2) After preserving a few branches to the native muscles, the thoracodorsal (TDN) and phrenic nerves (PhN) were transferred in an end to side fashion to the axillary nerve to reanimate shoulder abduction. Sural nerve grafts harvested

from the patient were used to link the transfer in light of the large gap noted between donor and recipient nerves. 10 and 15centimeter sural nerve grafts was applied to the TDN and PhN respectively. 3) The long thoracic nerve (LTN) was also utilized and transferred to re-innervate the triceps branch of the radial nerve through another 10centimeter sural graft to activate elbow extension. 4) A portion of healthy C5 nerve root was then routed to the suprascapular nerve via a nerve graft as well, to further activate the shoulder stabilizers (See table 2). Finally, Oberlin-1 and Oberlin-2 procedures were performed distally to restore elbow flexion.

Table 2. Procedures performed in each surgery.

Surgery	Intended function	Donor nerve/tendon	Recipient nerve/ tendon	Nerve graft (length)
1	Shoulder abduction	Thoracodorsal nerve	Axillary nerve	Sural nerve (10cm)
		Phrenic	Axillary nerve	Sural nerve (15 cm)
	Elbow extension	Long thoracic nerve	Nerve to triceps long head	Sural nerve (10cm)
	Shoulder stabilization	C5 nerve root	Suprascapular nerve	Sural nerve (10cm)
	Elbow Flexion	Median nerve fascicle	Biceps motor branch	Primary
		Ulnar nerve fascicle	Brachialis motor branch	Primary
2	Wrist extension	FCU fascicle (Ulnar N.)	Motor Branch to ECRB	Radial nerve graft 5 cm
	Finger extension	FDP fascicle (Ulnar N.)	Posterior Interosseous N	Radial nerve graft 5 cm
3	Extension of fingers, thumb	FCU	Combined extensors of wrist and fingers	Primary
4	Shoulder: External rotation	Latissimus Dorsi	Teres minor	Primary
5	Elbow extension	Thoracodorsal nerve	Motor branch to triceps	Sural nerve graft

After 3 months, the biceps, triceps and deltoid muscles clinically displayed evidence of early innervation. Both elbow flexion and extension could be actively performed along the plane of gravity and the shoulder muscles began to demonstrate contractions. A second surgery was then planned, now with the goal to improve active wrist and finger extension of the left upper extremity. During the second surgery, the patient underwent removal of the plate used for the fracture on this radial shaft. Using the same incision, the superficial radial nerve was identified, isolated and harvested to serve as vein graft. Single fascicles of ulnar nerve branches to the flexor digitorum profundus and flexor carpi ulnaris (FCU) were then isolated and transferred to the extensor carpi radialis brevis nerve and posterior interosseous nerves respectively via the superficial radial nerve graft (5cm each). Because there appeared to be a mismatch between the size of the donor and recipient nerves, the donor nerve, which was the smaller of the two, was placed centrally at the nerve end of the recipient nerve.

During follow up, shoulder abduction, elbow flexion and extension continued to improve. Wrist extension also improved but at a slightly slower rate than desired. Unfortunately, we did not document any improvement in active finger and thumb extension after observing the hand for 9 months post-op.

This lack of finger and thumb extension was causing a hindrance in hand function, and the patient was once more prepared for surgery. In this third surgery, a tendon transfer was performed. The FCU, which appeared to have 4+/5 motor strength inspite of previously harvesting its fascicles, was transferred to the combined tendons of thumb and finger extensors.

Further, to improve the clearance of the arm by providing external rotation, a latissimus dorsi muscle transfer to the teres

minor was done in a fourth surgery. The transfer was carefully carried out considering previous nerve transfers in the area.

The patient was closely monitored and compliant with physical therapy. Unfortunately, during the post-operative course of the patients fourth surgery, he developed a loss of active elbow extension. A significant tincl sign was noted over the upper posterior arm, and in view of a possible neuroma versus iatrogenic injury to previously placed nerve grafts, re-exploration was done. Intra-operatively, a neuroma-in-continuity at the previous nerve transfer was discovered. The intact fascicles could not be saved so the whole neuroma was excised. The proximal intact nerve was connected to the long head motor branch of the triceps, close to its entry into the muscle. This was the patients final surgical intervention for management of his injuries.

The patient was monitored for two more years after the last surgery. He was compliant with all rehabilitative measures. He had significant functional improvement and was able to perform light overhead activities (See table 1). His final left grip strength was 40 pounds and DASH scores were recorded in June 2011 at 52.5.

3. Discussion

BPI's are serious injuries with a protracted course of recovery irrespective of management. [2] The management of these injuries has evolved over time and for any given situation there are predictable suggested nerve donors as well as set principles we follow as guidelines. [2, 3] Systematic charting of available functioning muscles in the limb and vicinity is the first step. Long debate about timing of intervention, now seems to have settled in favor of exploration within 6 months from injury, the earlier the better, especially

when there is documented evidence of nerve disruption. [4-6] Exploration of the plexus and finding out the available proximal stumps is next. There is a recent trend of ignoring this step altogether with availability of reliable distal nerve transfers. [7]

A predictable set of nerve transfers, as per their availability, is preferred when no proximal roots are available. Successful outcomes in nerve transfer procedures and techniques are largely reliant to the fact that 1) nerve transfers usually are motor-motor or sensory-sensory nerve coaptations and 2) selected donor nerves are usually within close vicinity to their planned recipients, shortening time to reinnervation. There are instances when the use of grafts is unavoidable, such as in this case. When a nerve graft is needed, autologous grafts continue to be gold standard. In spite of this however, my must always keep in mind that technique of harvest and coaptation, tension or bunching at repair sites and nerve diameter sizing largely affect outcomes. We also know that as nerve grafts increase in length, time to reinnervation becomes a larger concern, threatening the success of an entire procedure. The choice to continue to use autologous nerve grafts over other options such as vein grafts and conduits, in spite of donor site morbidity, largely lie in the fact that outcomes following the use of nerve grafts in lengths such as in this case, are still best. [9, 10] Finally, functional muscle transfers and various sets of tendon transfers are useful procedures that continue to have a role in management of brachial plexus and peripheral nerve injuries. They provide results, not as excellent as nerve transfers but still serve as adjuvants, in scenarios where nerve transfers are unsuccessful or not available.

The presented case is from the era when various nerve transfer options were still evolving. After systematic charting of available muscles in our patient, he was indicated for surgery and the plexus was formally explored. Goals were to first, restore elbow flexion and possible shoulder abduction.

Upon exposure, the injury was extensive and the neuroma involved the C₅-C₇ roots from distal to neural foramen until below the clavicle. An attempt was made to identify healthy nerve roots proximally at the C₅-C₇ nerve roots where some healthy C₅ nerve root fascicles were found and were utilized for the suprascapular nerve.

Due to non-availability of the proximal roots, attention was diverted to other possible donor nerves. The spinal accessory nerve was explored but could not be identified because of the extensive scarring in the area. A decision was then made to explore other options. The PhN, TDN and LTN were easily identified and isolated.

The PhN has been well documented to be used as a donor nerve in brachial plexus injuries. Various publications have documented its use to restore elbow flexion through its transfer to the musculocutaneous nerve. Literature has also been published establishing PhN to musculocutaneous nerve success even with an interposing sural nerve graft, though exact lengths of grafts are not disclosed. [11, 12] In this case, the PhN was used for neurotization of the axillary nerve, through a 15cm sural nerve graft. Though the chosen combination is uncommon, the general principle of

re-innervating a nerve with a strong motor nerve donor makes it a theoretically sound choice.

The other nerves chosen in this case were less commonly used when performing nerve transfers. The surgical team was aware that the intercostals were available nerves donors as well but chose to preserve them since the phrenic was already exhausted and to preserve them for a possible second stage, where functional muscle transfer for elbow, wrist or finger extension would be necessary for the patient.

The TDN was identified, isolated and divided. 50% of the nerve fascicles were left alone to supply the latissimus dorsi muscle and the remaining 50% was then used and transferred to axillary nerve through a nerve graft. Reports of use of the TDN as a nerve graft have been published. IT was mentioned early on as a "viable choice" for axillary nerve re-innervation in an article by Nath, Mackinnon and Shenaq, [14] but actual techniques for its use were published later on by various authors for restoration of either elbow flexion or extension, none however requiring a nerve graft [13, 15].

The reason a double neurotization of the axillary nerve was preferred in this case was due to the questionable remaining strength of the TDN. Since a large part of the TDN's proximal innervation was affected by the neuroma, the phrenic nerve was also used to augment the transfer. The LTN was then harvested after its branch to the serratus anterior muscle and was used to reanimate the triceps. The LTN was and is a very uncommon choice for nerve transfers, that was made on the table. Publications exist describing it to be a recipient nerve but only one article by Vanaclocha et al, has mentioned it as a potential alternative nerve donor. In this article, it was recommended for restoring shoulder stability, not as an elbow extensor. [8]

Performing the chosen unconventional nerve transfers along with augmenting these transfers with relatively long nerve grafts was and is an unusual management choice. There are studies where nerve transfers with grafting have been done, and yielded outcomes similar to pure transfer procedures [11]. They failed to mention however, any length of graft used, that could help determine what would be acceptable and provide satisfactory results. On the other hand, one article by Wolfe et al demonstrated no difference in outcomes between pure long segment nerve grafting versus pure nerve transfers in patients with axillary nerve injuries. In his paper, grafts used were as long as 15 centimeters and muscle strength recovery was documented to be as high as 3-4/5 on final post operative assessment. [16] No literature is available describing procedures where nerve transfers are done while using long nerve graft augmentation, such as what was done in this case report.

To restore the patients elbow flexion, Oberlin transfers were done. This is a well accepted set of transfers to restore active elbow flexion. The 4/5 flexion of the elbow in the presented case, attests reliability of this transfer, as also suggested by multiple authors.

In the second surgery, nerve transfers done in the forearm have been described by Brunelli et al and are supposed to reanimate multiple muscles with a single transfer. The

movement and the aesthesia are also supposed to be superior in these patients. This transfer was attempted after waiting period of almost 6 months from the first surgery. Though the time frame in which the surgery was performed still falls into an acceptable window from injury, our results did not yield a complete success. The transfer for the wrist extension worked well, restoring muscle strength to 3/5, while finger extension did not, and tendon transfers had to be done at a later time to augment this function.

We would like to particularly mention the remarkable outcomes we had in this case after using the FCU multiple times a donor. An FCU nerve fascicle was first harvested during the Oberlin 1 and 2 transfer, which was successful, restoring elbow flexion. The nerve to the FCU was then used again to reanimate wrist extension. Finally, after donating fascicles to two separate muscle groups, FCU muscle function was still noted to be 4+/5 and was successfully transferred to actively provide finger and thumb extension.

The latissimus dorsi to teres minor transfer, is a well-known transfer in pediatric brachial plexus injuries, where the work the muscle has to do is limited. Its use is not very well mentioned in literature but with the favorable outcomes with its use in this report, we feel it is worth considering as an option for regaining shoulder external rotation in young adults.

Unfortunately, the donor nerve used to transfer to the Triceps was disturbed and patient's triceps function diminished after some time. We are unsure if the neuroma that developed in the area was from the initial surgery or because the nerve was disturbed during the latissimus muscle transfer (surgery #4). The neuroma nevertheless, was excised, and the fascicles from the thoracodorsal nerve were again harvested and connected to the long head branch to triceps, closer to the neuromuscular junction.

The repeated use of specific nerves as donors is worth highlighting in this report. The TDN was used twice throughout all procedures, yet the latissimus dorsi muscle was still able to display motor strength against gravity. Nerves to the FCU were also harvested for elbow flexion and finger extension, yet the FCU muscle was still strong enough to be used for tendon transfer. These events re-enforce previous publications indicating that as little as 20-40% of intact fascicles are all that is required by a muscle to maintain good strength and function.

4. Conclusion

BPI's are complex injuries that may prove difficult even for experienced microsurgeons. A thorough understanding of anatomy and nerve physiology is crucial when managing these cases. A set of recommended nerve transfers have been established in literature through the years, which have yielded good results. These transfers however, will not always be feasible to perform, particularly when the zone of injury in areas are long and extensive. Instances will also occur, when the most ideal nerves for transfer are not easy to identify.

This paper offers alternative donor nerves that can be

utilized when performing nerve transfers. The thoracodorsal and long thoracic nerves are not popularly used nerves, yet appeared to provide successful outcomes in this report.

The report was also able to demonstrate good results in nerve transfers where long autologous nerve grafts were utilized. Though we cannot recommend that long nerve grafts be used routinely, we do feel that their use in complex and difficult procedures is still worth considering.

Finally, we support current and emerging concepts of single fascicular nerve transfers. This technique was repeatedly used throughout the patients' course, so much so that some nerves were used as donors more than once. With proper technique this paper demonstrates that even after multiple single fascicular nerve transfers, terminal muscle tone can still be strong enough and remain viable options for tendon transfers, should the need arise.

References

- [1] Landers ZA, Jethanandani R, Lee SK, Mancuso CA, Seehaus M, Wolfe SW. The Psychological Impact of Adult Traumatic Brachial Plexus Injury. *J Hand Surg Am.* 2018; 43 (10): 950.e1-950.e6.
- [2] Thatte MR, Babhulkar S, Hiremath A. Brachial plexus injury in adults: Diagnosis and surgical treatment strategies. *Ann Indian Acad Neurol.* 2013 Jan-Mar; 16 (1): 26-33.
- [3] Liu Y, Lao J, Gao K, Gu Y, Xin Z. Outcome of nerve transfers for traumatic complete brachial plexus avulsion: results of 28 patients by DASH and NRS questionnaires. *Journal of Hand Surgery (European Volume).* 2012; 37 (5): 413-421.
- [4] Martin, E., Senders, J. T., DiRisio, A. C., Smith, T. R., & Broekman, M. D. (2018). Timing of surgery in traumatic brachial plexus injury: a systematic review, *Journal of Neurosurgery JNS*, 130 (4), 1333-1345. Retrieved Sep 16, 2020.
- [5] Birch R: Timing of surgical reconstruction for closed traumatic injury to the supraclavicular brachial plexus. *J Hand Surg Eur.* 2015; 40: 562-7.
- [6] Carlsen BT, Bishop AT, Shin AY: Late reconstruction for brachial plexus injury. *Neurosurg Clin N Am.* 2009; 20: 51-64.
- [7] Korus L, Ross DC, Doherty CD and Miller TA. Nerve Transfers and Neurotization in Peripheral Nerve Injury, from Surgery to Rehabilitation. *Journal of Neurology, Neurosurgery and Psychiatry.* 2016; 87: 188-197.
- [8] Houschyar KS, Momeni A, Pyles MN, Cha JY, Maan ZN, Duscher D, Jew OS, Siemers F, van Schoonhoven J. The Role of Current Techniques and Concepts in Peripheral Nerve Repair, *Plastic Surgery International*, vol. 2016, Article ID 4175293, 8 pages, 2016. <https://doi.org/10.1155/2016/4175293>.
- [9] Ray WZaps: Autografts, allografts, nerve transfers, and end to side neurorrhaphy. *Experimental Neurology* 223 (2010) pp 77-85.
- [10] Gu, Yu-dong; Use of the Phrenic Nerve for Brachial Plexus Reconstruction, *Clinical Orthopaedics and Related Research*: February 1996 - Volume 323 - Issue - p 119-121.

- [11] Liu Y, Lao J, Gao K, Gu Y, Zhao X. Comparative study of phrenic nerve transfers with and without nerve graft for elbow flexion after global brachial plexus injury. *Injury*. 2014; 45 (1): 227-231. doi: 10.1016/j.injury.2012.12.013.
- [12] Schusterman MA 2nd, Jindal R, Unadkat JV, Spiess AM. Lateral Branch of the Thoracodorsal Nerve (LaT Branch) Transfer for Biceps Reinnervation. *Plast Reconstr Surg Glob Open*. 2018; 6 (3): e1698. Published 2018 Mar 19. doi: 10.1097/GOX.0000000000001698.
- [13] Nath RK, Mackinnon SE, Shenaq SM. New nerve transfers following peripheral nerve injuries. *Operative techniques in plastic and reconstructive surgery*. 1997; 4 (1): 2-11. doi: 10.1016/S1071-0949(97)80012-1.
- [14] Soldado F, Ghizoni MF, Bertelli J. Thoracodorsal nerve transfer for triceps reinnervation in partial brachial plexus injuries: thoracodorsal nerve transfer to the triceps. *Microsurgery*. 2016; 36 (3): 191-197. doi: 10.1002/micr.22386.
- [15] Vanaclocha VV, Ortiz-Criado JM, Saiz-Sapena N, Vanaclocha N. Nerve Transfers in the Treatment of Peripheral Nerve Injuries. *Peripheral Nerve Regeneration – From New Therapeutic Approaches Including Biomaterials and Cell-Based Therapies Development*. 2017.
- [16] Wolfe SW, Johnsen PH, Lee SK, Feinberg JH. Long-nerve grafts and nerve transfers demonstrate comparable outcomes for axillary nerve injuries. *Journal of Hand Surgery*. 2014; 39 (7): 1351-1357.