



Dyke-Davidoff-Masson Syndrome: A Case Report in a Filipino Male Adolescent

Lalaine Villaflor-Oida*, Rowena Cabradilla, Michelle Sy, Alejandro Bimbo Diaz, Maria Antonia Aurora Valencia

University of Santo Tomas Hospital, Manila, Philippines

Email address:

lbvoida@gmail.com (Lalaine Villaflor-Oida)

*Corresponding author

To cite this article:

Lalaine Villaflor-Oida, Rowena Cabradilla, Michelle Sy, Alejandro Bimbo Diaz, Maria Antonia Aurora Valencia. Dyke-Davidoff-Masson Syndrome: A Case Report in a Filipino Male Adolescent. *International Journal of Clinical and Experimental Medical Sciences*. Vol. 9, No. 2, 2023, pp. 21-24. doi: 10.11648/j.ijcems.20230902.11

Received: June 6, 2022; **Accepted:** July 6, 2022; **Published:** May 10, 2023

Abstract: A previously well young Filipino boy presented with prolonged recurrent left focal to bilateral seizure. He was born of a non-consanguineous marriage, home-delivered vaginally, full term with no perinatal complications. He had normal growth and developmental milestones until at the age of 7 months when he developed febrile status epilepticus. Since then, he was left with residual left hemiplegia, dysarthria, cognitive delay and recurrent seizures occurring twice daily. He was poorly compliant on multiple anti-seizure medications. He was able to go to school and do activities of daily living with minimal supervision from his family. Symptoms of refractory seizures, hemiparesis, facial asymmetry, and intellectual disabilities along with brain imaging evidence of cerebral hemi-atrophy with compensatory calvarial thickening and subsequent hyperpneumatization is consistent with Dyke-Davidoff-Masson Syndrome (DDMS). A rare clinico-neuroradiologic condition occurring in fetal or early childhood period as a consequence of chronic brain insult. Diagnosis is established clinically with a characteristic cranial imaging finding. Hemi-spherectomy is the treatment of choice. This case will enlighten our mind as well as aid us in the prompt recognition of this uncommon syndrome with a classic clinico-radiologic presentation. Multidisciplinary intervention is essential, primarily to optimize seizure control as well as provide quality of life.

Keywords: Dyke-Davidoff-Masson Syndrome (DDMS), Filipino, Adolescent

1. Introduction

In 1933, three scientists first described Dyke-Davidoff-Masson Syndrome (DDMS) by plain skull radiographic and pneumato-encephalographic changes in a series of nine patients. It is characterized by cerebral hemi-atrophy, or hypoplasia with compensatory changes in ipsilateral cranial vault and subsequent enlargement of frontal and ethmoid sinuses. Clinically depicted by refractory seizures, facial-asymmetry, hemiparesis and developmental delay [1]. The left hemisphere and male sex predominance was frequently involved [4]. Although multiple case reports were mentioned but no reported data among Filipino children was published to date.

2. Case Report

A 17-year-old male who presented with recurrent left focal seizure with secondary generalization. He was born of a non-consanguineous marriage, home-delivered vaginally at full term with no perinatal complications. He had normal growth and developmental milestones until at 7-months-old when he had complex febrile seizure, which started as upward rolling of eyeballs with left upper and lower extremity tonic-clonic posturing followed by circumoral cyanosis, drooling, urine and fecal incontinence. Following to seizure, he did not regain consciousness until the 8th hour. He was brought to a local hospital where he was treated for 2 weeks. CSF analysis, cranial ultrasound and subsequently CT scan, revealed unremarkable result. Since then he was left with residual left hemiplegia,

dysarthria, cognitive delay and recurrent seizures occurring twice daily. He was able to go to school with minimal supervision from his family for hygiene and safety. Since then neither medical consult provided, nor medications given, thereafter, until he had repeated seizure at the age of 16. He was brought to a neurologist where levetiracetam and valproic acid 500mg each given once daily. Neuro-diagnostics such as electroencephalogram (EEG) and cranial CT scan were done then had declining bouts. EEG result was lost while plain cranial CT scan revealed right cerebral hemiatrophy, ipsilateral dilatation of lateral ventricle, right frontal sinus hyperpneumatization and ipsilateral thickening of cranial vault. A year after, he developed super-refractory status epilepticus hence admitted under critical care service.

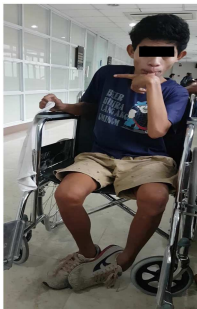

Figure 1. Image of the patient 3 months after super refractory seizure. He is wheelchair borne with left hemiparesis, left facial asymmetry, muscle wasting and generalized spasticity.

He is on elementary grade, youngest among brood of seven with no family history of epilepsy or developmental delay. He had no neurocutaneous lesion or dysmorphic feature, wheelchair borne, uncooperative, no verbal output, very fidgety, had visual tracking, drooling and exhibit upper motor neuron signs in the form of spasticity, left hemiparesis, hyperreflexia and left extensor plantar reflex.

The EEG revealed asymmetric background slowing of the left head region with intermittent spikes predominantly arising over the right fronto-central leads. Consistent findings were seen on repeat plain cranial CT scan. He was discharged with levetiracetam 500mg twice daily and perampnel 4mg twice daily. Well controlled seizure was noted on serial follow-up consult hence anticonvulsants were maintained.

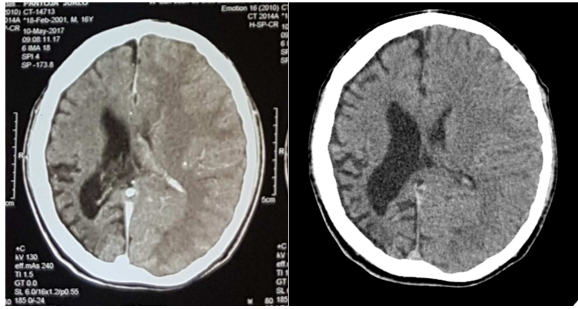


Figure 2. Plain cranial CT scan done in 2017 (above) and 2018 (below) showing right hemisphere atrophy, right frontal sinus hyperpneumatization widening of the right lateral ventricle and compensatory thickening of the calvarium.

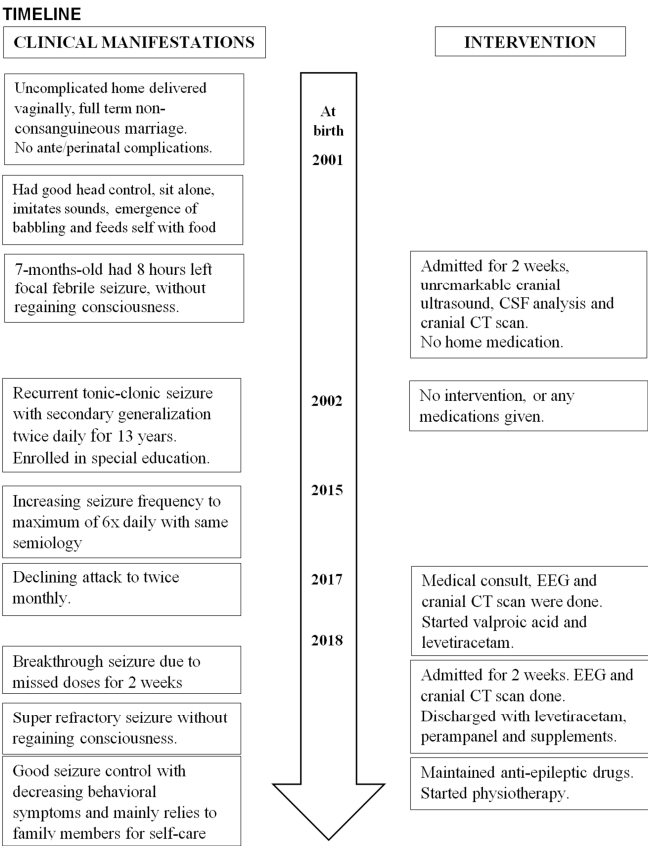


Figure 3. Timeline of patient's clinical manifestation and intervention done.

3. Discussion

In 1939, Alpers and Dear defined two types of cerebral hemiatrophy [2]. These are the primary or congenital type and secondary or acquired type results from a cerebrovascular lesion, prolonged febrile seizure, infectious or trauma. Common pathway is an insult in developing brain during intrauterine to early childhood. The brain reaches half of its adult size during the first year of life and three-fourths size by the end of third year. As it enlarges, the brain presses outward on the bony tables and is responsible for the gradual enlargement and general shape of the adult head. When the brain fails to grow appropriately other structures will direct their growth inward, thus accounting for the enlargement of the frontal sinus, the increased width of the diploic space and the elevations of the greater wing of sphenoid and the petrous ridge on the affected side. These changes can occur only when brain damage is sustained before three years of age however, such changes may become evident as soon as nine months after brain damage was sustained [3].

Involvement of both genders and hemispheres has been reported but the disease is more common in men and more often involve the left hemisphere. In younger age group, right hemispheric cerebral blood flow predominance predisposes the contralateral hemisphere to be sensitive to cortical damage. Functionally, men are more hemispherically asymmetric relative to women and this may reflect differences in neuronal connectivity, it was also hypothesized that the presence of circulating androgens may generate a 'hyperplastic' condition such that there is more extensive neuronal remodeling after injury than in female brain [4].

Bhargava, et al enrolled 32 patients in an observational hospital-based cohort study of clinico-radiological variability expansion in DDMS or hemiplegia, hemiatrophy and epilepsy (HHE). Majority were males with the mean age of 8-42 years old. Twenty-eight patients presented with DDMS, three Rasmussen encephalitis and two HHE syndromes. Congenital type and seizure refractory were common presentation. In acquired cases, febrile encephalopathy irrespective of etiology at 3 to 10 years of life is most common finding, with 2.4 (± 1.82) times of seizure per month for a total of 24.09 (± 9.3) years of epilepsy. MRI findings showed left lateralization with holo-hemispheric atrophy, cerebellar atrophy, calvarial thickening with frontal sinus hyperpneumatization. Epileptiform activity was concordant to lesion. Remarkably DDMS/HHE can present protean clinico-radiological manifestation, cerebellar atrophy and hippocampal sclerosis [5]. In line with this, case reports discussed comparable clinic-radiologic presentation among pediatric DDMS [6, 7, 8, 9, 11].

Because of the limited experience in recognition and management of DDMS, no treatment guidelines were established. Management is largely symptomatic in the form of adequate control of seizures and behavioral manifestations. Functional hemispherectomy showed

effective among with refractory seizures [10]. It has also been seen that prognosis may be better in patients in whom hemiparesis appeared after 2 years of age or in whom the seizures were not recurrent. Although it is not necessary to do neuroimaging in every pediatric case presenting with febrile seizures, it should be considered in those who presented with recurrent and refractory seizure with neurobehavioral manifestations so that one does not miss out on the diagnosis [8].

4. Conclusion

The present case will enlighten our minds on DDMS as one of the consequences of status epilepticus, its classic clinico-radiologic presentation as well as prompt recognition of this uncommon syndrome.

Informed Consent

The informed consent was explained to the parents in a simple language they understand. Information taken from the patient was de-identified and will remain confidential at all times. The mother of the patient signed a written informed consent in English as the preferred language before writing this case report. The patient has intellectual disability hence cannot assent in his behalf. An IRB approval will be likewise obtained.

Acknowledgements

There is no conflict of interest recognized with the writing of this article nor any funding being received.

References

- [1] Dyke CG, Davidoff LM, Masson CB. Cerebral hemiatrophy and homolateral hypertrophy of the skull and sinuses. *Surg Gynecol Obstet* 1933; 57: 588-600.
- [2] Alpers BJ and Dear RB. Hemiatrophy of the brain. *J Nerv Ment Dis* 1939; 89: 653-651.
- [3] Sharma, et al. Dyke-Davidoff Masson Syndrome *Ind J Radiol Imag* 2006 16: 2: 165-166.
- [4] Ozkan Unala, et al. Left hemisphere and male sex dominance of cerebral hemiatrophy (Dyke Davidoff-Masson Syndrome). *Journal of Clinical Imaging* 28 (2004) 163-165.
- [5] Amita Bhargava, et al. Dyke-Davidoff-Masson syndrome: A study of clinico-radiological variability in hemiplegia, hemiatrophy and epilepsy patients. *Journal of Health and Research /Vol 1/Issue 3/ Jul-Sep 2014.*
- [6] Vipin Ola, et al. Dyke – Davidoff- Masson Syndrome. *Journal of the association of physicians of India.* January 2014, vol 62.
- [7] Jun Hwa Lee et al. A case of Dyke Davidoff Masson syndrome in Korea. *Korean Journal of Pediatrics* Vol 49. No 2, 2006; 49: 208-211.

- [8] Mehtab Alam¹, et al. Dyke-Davidoff-Masson Syndrome: An Unusual Cause of Status Epilepticus and Refractory Seizures. *Journal of the College of Physicians and Surgeons Pakistan* 2018, Vol. 28 (Special Supplement 2 of Case Reports): S99-S101.
- [9] Jitender Aneja, et al. Acquired Dyke-Davidoff-Masson syndrome (DDMS). *Advanced Medical and Health Research* | Volume 2, Issue 1. Jan-Jun 2015.
- [10] McMonagle et al. The cognitive profile of posterior cortical atrophy. *Neurology* 2006; 66: 331-8.
- [11] Urs, G. M., & R. Doddabele, H. (2022). Dyke-Davidoff-Masson Syndrome: A Case Report. *International Journal of Medical Students*, 10 (1), 82–85.