



Analysis of a Case of Colon Cancer Complicated with Diffuse Large B-Cell Lymphoma of the Spleen

Guoqing Huang, Chulin Liang, Mingzhi Sang, Xuyou Liu

Department of Gastroenterology, Guangzhou Red Cross Hospital, Jinan University, Guangzhou, China

Email address:

hgq35351060@163.com (Guoqing Huang), churlinleung@outlook.com (Chulin Liang), mz_sang371@163.com (Mingzhi Sang),

liuxy717@163.com (Xuyou Liu)

To cite this article:

Guoqing Huang, Chulin Liang, Mingzhi Sang, Xuyou Liu. Analysis of a Case of Colon Cancer Complicated with Diffuse Large B-Cell Lymphoma of the Spleen. *International Journal of Clinical and Experimental Medical Sciences*. Vol. 9, No. 5, 2023, pp. 79-84.

doi: 10.11648/j.ijcems.20230905.12

Received: September 26, 2023; **Accepted:** October 20, 2023; **Published:** October 31, 2023

Abstract: *Background:* Primary splenic lymphoma (PSL) is a rare type of tumor that occurs in the spleen, generally without the involvement of intrasplenic organs and lymph nodes, and its incidence is less than 1% of lymphomas, most of which are non-Hodgkin's lymphomas (NHL). Diffuse large B-cell lymphoma (DL- BCL) often has atypical clinical manifestations, which makes clinical diagnosis difficult and is prone to misdiagnosis or omission, posing a significant challenge to clinical diagnosis and treatment. Colorectal cancer is the third most frequent cancer and the fourth most common cause of death in the world and is diagnosed on the basis of clinical manifestations, X-ray barium enema, or fiberoptic colonoscopy. The key to colorectal cancer treatment lies in early detection, timely diagnosis, and surgical eradication. Although lymphoma and colorectal cancer are some of the most frequent malignant tumours in adults, and there are guidelines for the diagnosis and treatment of both diseases, their co-occurrence is extremely uncommon, and there are fewer reports in the literature on the diagnosis and treatment of co-existing cases, and there is still no definitive and effective method for diagnosis, differential diagnosis and treatment. A case of splenic diffuse large B-cell lymphoma complicated with colon cancer was admitted to our hospital, and we now report its clinical data, conduct a literature review and analysis in order better to carry out clinical diagnosis, differential diagnosis and treatment, and summarize the diagnosis and comprehensive treatment experience of this disease. This case report provides ideas for the diagnosis and treatment of the disease.

Keywords: Primary Splenic Lymphoma, Diffuse Large B-Cell Lymphoma, Colon Cancer

1. Introduction

Primary splenic lymphoma (primary splenic lymphoma, PSL) is a rare tumor that occurs in the spleen, usually without involvement of intrasplenic organs and lymph nodes, and its incidence is less than 1% of lymphoma, mostly non-Hodgkin Gold lymphoma (NHL); diffuse large B-cell lymphoma (DL-BCL) is clinically more aggressive, often due to the lack of specific clinical manifestations, clinical diagnosis is complex, and misdiagnosis or missed diagnosis is prone to occur. Colorectal cancer is the third most common cancer and the fourth most common cause of death worldwide and is diagnosed on the basis of clinical manifestations, X-ray barium enema, or fiberoptic colonoscopy. The key to colorectal cancer treatment lies in early detection, timely diagnosis, and surgical eradication.

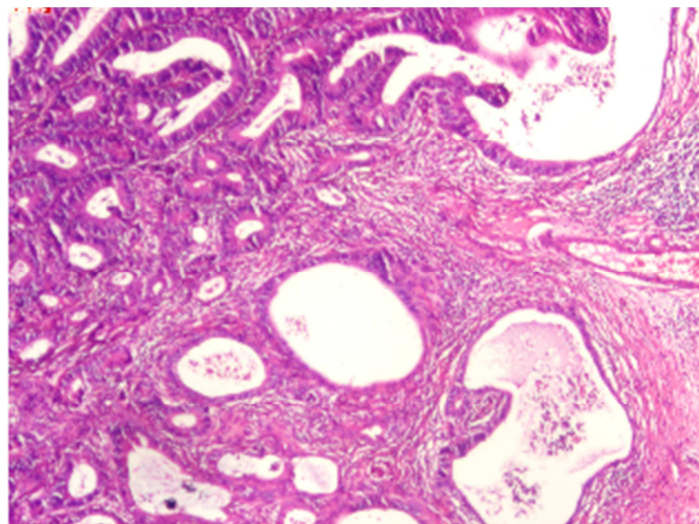
Although lymphoma and colorectal cancer are among the most common malignancies in adults, their co-occurrence is extremely rare. There are few reports on the diagnosis and treatment of cases, and there are still no clear and effective methods for diagnosis, differential diagnosis, and treatment. Therefore, it is simple to misdiagnose or miss the diagnosis in the clinical diagnosis and treatment of such analogous cases, particularly when the splenic space-occupying lesions are misunderstood as metastatic lesions of colorectal cancer, which may delay the best time for treatment. Presently, the diagnosis and treatment strategy for this disease still require to be developed with the support of a considerable number of clinical cases and applicable laboratory data. A patient with colon cancer complicated with splenic diffuse large B-cell lymphoma was admitted to our hospital. The clinical data are, at this moment, reported

and reviewed. There is summarizing the experience of diagnosis and comprehensive treatment of the disease.

2. Case Presentation

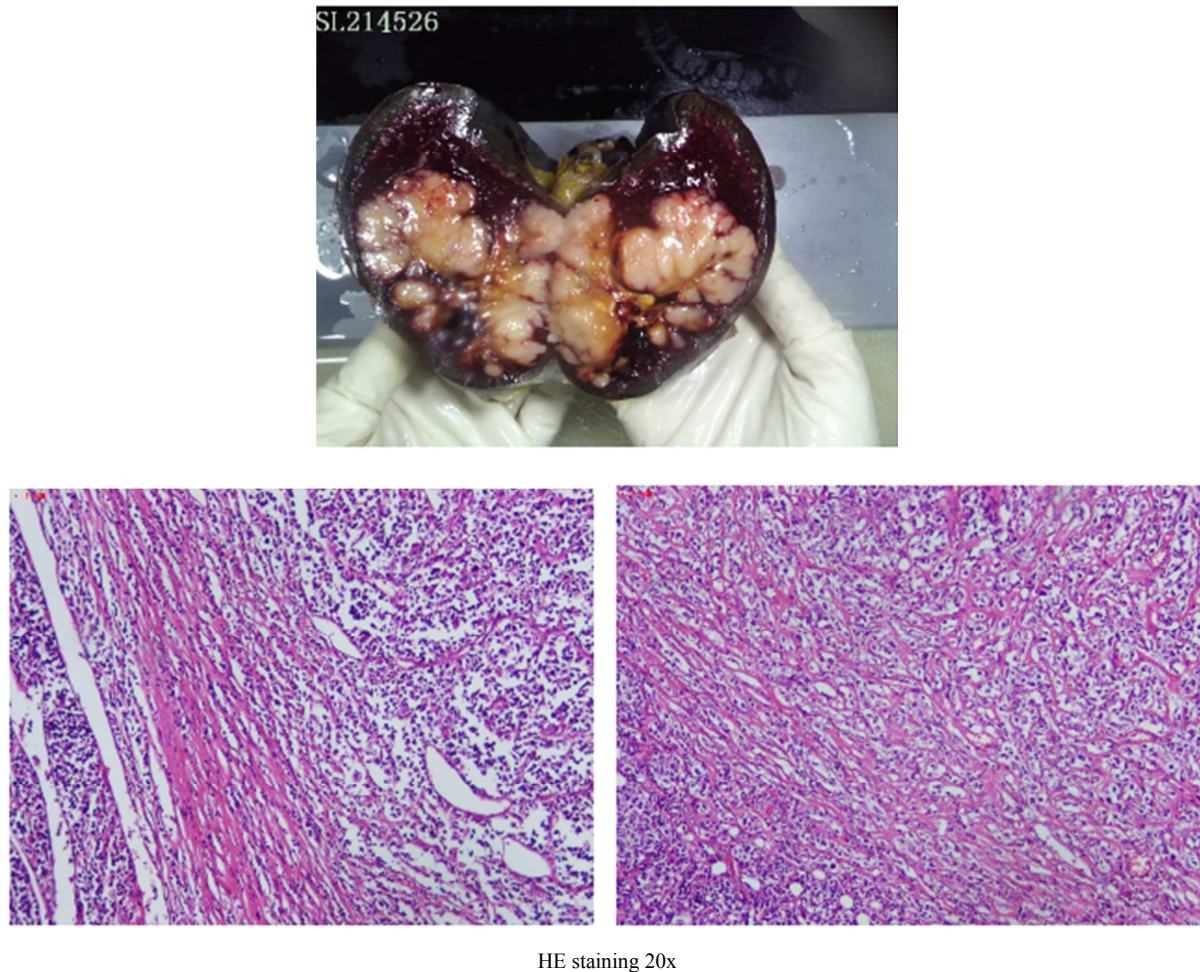
The female patient, 83 years old, was admitted to the Gastroenterology Department of our hospital on June 29, 2021, due to epigastric pain and poor appetite for two months. Epigastric pain appeared two months ago, mainly under the xiphoid process, showing paroxysmal dull pain, obvious when hungry, relieved after eating, accompanied by anorexia, fatigue, nausea, dizziness, occasional heating, stool 1-2 Time/day; it is yellow shaped stool. Since the onset of the disease, the spirit, sleep and appetite are poor, the stool is as above, and the urine is as usual. Recently, she has lost weight significantly (specifically unknown). Physical examination: clear mind, anemic appearance, no yellow staining of skin and mucous membranes, no enlarged superficial lymph nodes, no abnormalities in heart and lungs, flat, soft abdomen, no tenderness and rebound pain, Murphy sign (-), liver and spleen The ribs are not reached, and the mobility turbidity was harmful. Relevant tests were completed after admission: blood routine: RBC $3.18 \times 10^9/L$, HGB $91g/L$, blood biochemistry: blood K 2.69 mmol/l , creatinine 153.8umol/l , estimated glomerular filtration rate 26.8 , albumin $31.1g/l$, lactate dehydrogenase $482U/L$, uric acid 577umol/l . Coagulation function: Activated partial thromboplastin time (APTT) was 37.3 seconds, and the remaining PT, INR, and TT were regular. Abdominal CT plain scan + enhanced tips: 1. The transverse colon splenic flexure wall is slightly thickened, and malignant space-occupying cannot be ruled out; 2. Multiple space-occupying lesions in the spleen: metastases?; 3. Multiple cystic low-density lesions in the liver, large Some are cysts; 4. Spongy expansion of the left portal vein and portal-left hepatic vein fistula; 5. Gallbladder stones (2), chronic cholecystitis. The intrahepatic bile ducts

were mildly dilated. Mild expansion of the pancreatic duct; 6. Multiple cysts in both kidneys. There were multiple tiny calculi in bilateral calyces, stones in the ureteral opening of the right renal pelvis, and mild effusion in the right renal pelvis. The carbon 14 breath test was positive. Gastroscopy tips: 1. Antrum duodenal ulcer in active stage (A2); 2. Chronic gastritis with erosion (sinus). Gastric mucosal biopsy: chronic active inflammation of "gastric antrum" mucosa with local mucosal erosion, moderate to severe intestinal metaplasia of glandular epithelium. Colonoscopy showed: 1. Ascending colon polyps 2. Endoscopic removal of intestinal polyps 3. Colon melanosis 4. Hemorrhoids; Intestinal mucosal biopsy: 1. "Ascending colon" mucosal tubular adenoma; 2. "Transverse colon" mucosal adenocarcinoma". The primary preoperative diagnosis of the patient was: 1. Transverse colon cancer 2. Splenic space-occupying: The metastatic tumor is waiting to be discharged. On July 13, 2021, laparoscopic left hemicolectomy radical resection + splenectomy + peristomal, middle group, and central group lymph node dissection were performed under general anesthesia. Pathological hints: 1. Left hemicolectomy: "transverse colon" raised moderately differentiated tubular adenocarcinoma (tumor volume $1.1 \times 1 \times 0.4\text{cm}$, 7.5cm away from one side's resection margin, and 30cm from the other side's resection margin), cancer tissue infiltrated the deep muscle of intestinal wall. There was no clear intraluminal embolus of cancer, no apparent invasion of the nerve bundle membrane, and no cancer at the cutting edge of both ends of the colon taken from the left half of the colon. See Figure 1. 2. Lymph node resection of the central group: No cancer was found in the lymph nodes of the "central group" Metastasis: 0/5; One of the lymph nodes was B-cell lymphoma, which was considered to be of the exact origin as the spleen tumor. 3. Splenectomy: "Spleen" non-Hodgkin's lymphoma, B-cell, considered diffuse large B-cell lymphoma, activated B-cell. See Figure 2.



HE staining 20x

Figure 1. The pathology of the tumor in the left colon shows that the tumor tissue is composed of cord-like, tubular, back-to-back, and cribriform glands, with prominent atypia of epithelial cells, significant and deeply stained nuclei, prominent nucleoli, and visible mitotic figures; Part of the glandular lumen ruptured, forming irregularly scattered nests of tumor cells, and some necrotic matter remained in the glandular lumen. Diagnosis: consistent with "transverse colon" raised type moderately differentiated tubular adenocarcinoma.



HE staining 20x

Figure 2. The pathology of the spleen specimen submitted for examination showed diffuse growth of tumor cells; the tumor cells were medium to small in size, oval in shape, some nuclear grooves were visible, some nucleoli were bordered, mitotic figures were visible, and the cytoplasm was less, tumor Fibrous tissue proliferation can be seen between the cells. Diagnosis: consistent with diffuse large B-cell lymphoma, activated B-cell.

After the operation, the patient's diagnosis was corrected according to the pathological results: 1. Transverse colon bulging moderately differentiated tubular adenocarcinoma; 2. Diffuse large B-cell lymphoma of the spleen. Anti-infection, heart function protection, fluid replacement, acid suppression and gastric protection were strengthened after operation. After treatment, the condition recovers well, and it is recommended that the patient be given active chemotherapy to prevent recurrence. After multidisciplinary consultation and the wishes of the patient and the patient's family, given the patient's age, poor condition, and potential intolerance to chemotherapy, the patient was discharged without R-CHOP chemotherapy. During the follow-up to track changes in the condition, the patient, in this case, died of heart failure four months after discharge, and the patient did not receive any treatment, including chemotherapy, after discharge.

3. Discussion

Multiple primary cancers (MPCs) are defined as two or more unrelated primary malignancies originating from one or more organs of the same host and occurring simultaneously or sequentially in the body [1]. According to the interval between

two cancers, if the diagnosis interval in MPC is ≤ 6 months, MPC is synchronous; MPC is metachronous if the interval is >6 months [2]. Co-occurrence of solid tumors with hematological malignancies is extremely rare, but co-occurrence of colorectal cancer and lymphoma is even rarer, estimated at 0.0002% [3]. Regarding the relationship between colorectal cancer and non-Hodgkin's lymphoma, Srikumar et al. [4] believed that lymphoma might be the initial event that inhibits the development of resistance to colorectal cancer in patients. The body with lymphoma may appear Decreased immunosurveillance is accompanied by the promotion of adenocarcinoma cell growth, in a similar case reported by Hopster et al. [5, 6] in the presence of coexisting multiple primary carcinomas either co-occurred with intestinal lymphoma or was diagnosed after lymphoma diagnosis, suggesting an association between the two malignancies. On the other hand, Hirano et al. [7] reported a patient with hereditary nonpolyposis colorectal cancer who developed non-Hodgkin's lymphoma after radical resection of colorectal cancer. Among them, both colorectal cancer and lymphoma showed microsatellite DNA instability, sharing changes at the chromosome 7 (D7S501) locus, suggesting that there may be a common node in the pathogenesis of the two

diseases. In this case, the patient's clinical symptoms were not typical, only upper abdominal pain, fatigue, anorexia and other symptoms, and the medical history was only two months. Both diseases were diagnosed at the same time by postoperative pathological biopsy. More clinical case data are needed to clarify the relationship between the two diseases. Nonetheless, the rarity of such cases precludes the availability of sufficient data to support any definitive pathophysiological relationship between lymphoma and colorectal adenocarcinoma.

PSL refers to lesions that first appear in the spleen or splenic hilar lymph nodes and may be accompanied by a few abdominal lymph nodes, bone marrow, and liver invasion, and generally, there is no superficial lymphadenopathy. The incidence of PSL is low. Among the causes of splenomegaly, primary spleen lymphoma accounts for about 1%, mainly occurring in middle-aged and older adults. [8] Due to the rare disease and atypical clinical manifestations, some patients with PSL have no apparent symptoms in the early stage or only have left upper quadrant discomfort and fatigue. Supported by the clinical manifestations of epigastric pain, fatigue, anorexia, and weight loss, and without the support of pathological results, it is easy to be ignored or misdiagnosed as colon cancer with spleen metastasis in the early stage of the disease. It is necessary to pay attention to the degree of attention and differential diagnosis of B-cell lymphoma [9] to avoid missed diagnosis or misdiagnosis as splenic metastases, which may cause delays in clinical treatment. The clinical manifestations of PSL are non-specific, and the pathological types are diverse, making it difficult to diagnose. Before diagnosing lymphoma, clinicians should avoid splenomegaly caused by various infections, liver diseases, hemolytic diseases, etc. [10]. Although imaging can provide hints of splenic space occupation, it cannot make a definite diagnosis, and various diagnostic methods should be comprehensively applied. The b-ultrasound examination is simple and quick, but it is challenging to identify the nature of the tumor, and the diagnostic sensitivity for splenic lymphoma is 50% [11]. At present, the qualitative examination of spleen masses is mainly based on enhanced CT examination [12], in which not only the abdominal cavity, liver, gastrointestinal tract, and other organ tissues can be found but also can show the nature of spleen tumors and further provide a basis for disease staging. The coincidence rate of CT diagnosis of spleen tumors is as high as 90% [13]. Therefore, abdominal CT should be the first choice in clinical lymphoma diagnosis. In previous reports, scholars such as Maglione *et al.* [14] believed that in the course of disease development, imaging changes such as the gradual enlargement of the spleen are an essential basis for the diagnosis of PSL. In addition, fine-needle aspiration biopsy of the spleen is rarely used clinically due to the easy bleeding of the spleen, difficulty in positioning, and metastasis [12]. However, with the development of imaging and puncture technology, when conditions permit, Splenic biopsy can be improved to clarify the nature of the space-occupying tumor, differentiate metastases from

lymphoma, and avoid misdiagnosis. Presently, pathological biopsy of specimens after splenectomy is still the final basis for diagnosis. It is essential in diagnosing colon cancer with splenic metastasis and colon cancer with splenic lymphoma. In the case of colon cancer with splenic metastasis, no apparent metastasis was found in the liver, spleen, and other organs before the operation. After regular outpatient follow-up visits for colon cancer or gastrointestinal symptoms, spleen metastasis is often discovered after complete abdominal CT and other examinations. After colon cancer surgery, it is often combined with modified FOLFOX6 chemotherapy. After splenic metastasis is suspected, radical splenectomy combined with FOLFIRI chemotherapy is performed. However, the primary treatment for colon cancer combined with splenic lymphoma is radical resection combined with R-CHOP chemotherapy after surgery. The difference in preoperative and postoperative treatment between the two determines that we must make a timely diagnosis and choose an appropriate treatment plan. To avoid missed diagnosis and misdiagnosis and delay the timing of treatment. According to the existing research progress, we mainly rely on imaging examination and surgical pathological results to identify.

The treatment of colon cancer complicated with splenic diffuse large B-cell lymphoma has not yet had a unified diagnosis and treatment plan due to the minimal number of cases. The primary treatment method is still radical resection combined with postoperative chemotherapy, such as the R-CHOP regimen [15]. Radical splenectomy is the first choice for treating primary malignant tumors of the spleen, supplemented by postoperative radiotherapy and chemotherapy. According to the early stage [16]. Stage I tumor is located in the spleen; stage II tumor invades the splenic hilar lymph nodes; stage III tumor With liver or intra-abdominal lymph node metastasis. Surgical treatment was selected according to the stage. Splenectomy was performed in stage I and splenectomy and hilar lymph node dissection were performed in stages II and III. If the preoperative diagnosis of the nature of malignant splenic tumors is not precise, and it is not possible to determine whether it is a primary malignant tumor or a secondary metastatic tumor, the primary malignant tumor that may be associated with the malignant tumor of the spleen can be cured and resected, which should be selected. The corresponding organs were combined with radical surgery, and the next step of radiotherapy and chemotherapy was guided according to the pathological results after surgery [16]. Surgery can significantly improve the survival rate of patients, and postoperative chemotherapy and radiotherapy can be used to prevent recurrence, which can significantly improve the survival rate of patients. Pantoja [17] proposed that the specific treatment plan should be determined according to which malignant tumor mainly comes from the actual clinical manifestations of the patient. In his report, the patient's symptoms were all from abdominal lymphoma, so the patient received three courses of R-CHOP Chemotherapy and completed colorectal adenocarcinoma resection.

Therefore, the patient's clinical manifestations in this case were atypical and tended toward colon cancer. Considering the limited routine diagnostic methods for splenic lymphoma, splenectomy, and radical colon cancer resection were performed. Active chemotherapy was also recommended for patients with PSL to improve. However, given the patient's age, poor condition, and potential intolerance to chemotherapy, the patient did not receive relevant radiotherapy and chemotherapy after surgery and died of heart failure four months after discharge. According to the data, early splenectomy can help improve the survival rate. However, splenectomy cannot effectively treat lymphoma infiltration and distant metastasis outside the spleen for those with distant metastasis. There are few research reports on the efficacy of primary splenic DLBCL. Grosskreutz et al. [18] reported 8 cases (4 cases were low-risk, 2 were low-medium risk, and one was high-risk and high-risk by IPI score). Resection followed by CHOP regimen (cyclophosphamide, doxorubicin, vincristine, and prednisone) combined with chemotherapy, followed up for 1-19 years, is still in remission; Kim et al. [19] reported 3 cases (1 case at stage I, 2 cases at stage III), the treatment method was the same as above, and the patients were still in remission. It can be seen that splenectomy followed by combined chemotherapy can significantly improve the survival time of primary splenic DLBCL; whether radiotherapy can improve prognostic significance is unclear.

4. Conclusion

In summary, colon cancer combined with splenic diffuse large B-cell lymphoma is a scarce condition. The rare cases make the pathophysiological mechanism of the combination of the two still unclear, and its clinical manifestations usually lack specificity. It is prone to be missed or misdiagnosed clinically, and more attention should be paid to it. In terms of diagnosis, the pathological results after diagnostic resection are still used as the gold standard, and the preoperative diagnosis is mainly based on endoscopic mucosal biopsy and chest and abdomen CT scans. Spleen fine-needle biopsy can reduce the misdiagnosis rate of spleen tumors, supplemented by bone marrow biopsy and other examinations to check for hematological malignancies. For colon cancer complicated with splenic lymphoma, the primary treatment is still radical resection of colorectal adenocarcinoma + radical splenectomy, and postoperative chemotherapy combined with R-CHOP regimen can improve the prognosis of such patients. The difficulty of diagnosis and the complexity of treatment pose a considerable challenge to the treatment plan for such diseases. It is necessary to consider the specific treatment mode in a multidisciplinary and patient-centered manner and determine the best treatment strategy.

Funding

National Natural Science Foundation of China: 81972211.

References

- [1] Xu LL, Gu KS. Clinical retrospective analysis of cases with multiple primary malignant neoplasms. *Genet Mol Res.* 2014; 13(4): 9271-9284.
- [2] Shuangshuang Chen, Rui Ma. Research progress in multiple primary cancers [J]. *Cancer Progress.* 2019. 17(08): 883-886.
- [3] Barron BA, Localio SA. A statistical note on the association of colorectal cancer and lymphoma. *Am J Epidemiol.* 1976; 104(5): 517-522.
- [4] Srikumar T, Markow M, Centeno B, et al. Synchronous rectal adenocarcinoma and splenic marginal zone lymphoma. *Curr Oncol.* 2016; 23(1): e70-e74.
- [5] Hopster D, Smith PA, Nash JR, Elders K, Poston GJ. Synchronous multiple lymphomatous polyposis and adenocarcinoma in the large bowel. *Postgrad Med J.* 1995; 71(837): 443.
- [6] Wagle SD, Mohandas KM, Vazifdar KF, et al. Synchronous adenocarcinoma and lymphoma of the colon. *Indian J Gastroenterol.* 1997; 16(1): 28-2.
- [7] Hirano K, Yamashita K, Yamashita N, et al. Non-Hodgkin's lymphoma in a patient with probable hereditary nonpolyposis colon cancer: report of a case and review of the literature. *Dis Colon Rectum.* 2002; 45(2): 273-279.
- [8] Yunpeng Huang, Zong Zhang, Chaoting Liu, Liping Su. Clinical analysis of primary splenic lymphoma [J]. *Clinical Medicine Practice.* 2017, 26(12): 922-924.
- [9] Tseng CE, Shu TW, Lin CW, Liao KS. Synchronous adenocarcinoma and extranodal natural killer/T-cell lymphoma of the colon: a case report and literature review. *World J Gastroenterol.* 2013; 19(11): 1850-1854.
- [10] Pozo AL, Godfrey EM, Bowles KM. Splenomegaly: investigation, diagnosis and management. *Blood Rev.* 2009; 23(3): 105-111.
- [11] Görg C, Faoro C, Bert T, Tebbe J, Neesse A, Wilhelm C. Contrast enhanced ultrasound of splenic lymphoma involvement. *Eur J Radiol.* 2011; 80(2): 169-174.
- [12] Eloubeidi MA, Chen VK, Eltoun IA, et al. Endoscopic ultrasound-guided fine needle aspiration biopsy of patients with suspected pancreatic cancer: diagnostic accuracy and acute and 30-day complications. *Am J Gastroenterol.* 2003; 98(12): 2663-2668.
- [13] Dongxin Wang, Hongyong Jin, Xin Jiang, Xuanwen Liu, Zhuo Liu. A case report and literature review of splenic diffuse large B-cell lymphoma [J]. *Chinese Experimental Diagnostics.* 2013, 17(11): 2104-2105.
- [14] Maglione T, Yong S, Velankar M, Brems J. Image of the month: primary splenic high-grade lymphoma. *Arch Surg.* 2009; 144(7): 691-692.
- [15] Bennett M, Schechter GP. Treatment of splenic marginal zone lymphoma: splenectomy versus rituximab. *Semin Hematol.* 2010; 47(2): 143-147.
- [16] Yang Lu. Analysis of clinical diagnosis and surgical treatment of splenic space-occupying lesions [D]. *China Medical University.* 2018.

- [17] Pantoja Pachajoa DA, Bruno MA, Alvarez FA, Viscido G, Mandojana F, Doniquian A. Multiple primary tumors: Colorectal carcinoma and non-Hodgkin's lymphoma. *Int J Surg Case Rep.* 2018; 48: 92–94.
- [18] Grosskreutz C, Troy K, Cuttner J. Primary splenic lymphoma: report of 10 cases using the REAL classification. *Cancer Invest.* 2002; 20(5-6): 749-753.
- [19] Morel P, Dupriez B, Gosselin B, et al. Role of early splenectomy in malignant lymphomas with prominent splenic involvement (primary lymphomas of the spleen). A study of 59 cases. *Cancer.* 1993; 71(1): 207-215.